

Effect of EDTA Chelation and Supportive Multivitamin Trace Mineral Supplementation on Carotid Circulation: Case Report

**Charles J. Rudolph DO, PhD,
Edward W. McDonagh DO, ACGP**

ABSTRACT: A single patient with severe carotid occlusive disease and visibly evident shear motion in her right carotid artery was treated with intravenous infusions of disodium ethylene diamine tetracetic acid (EDTA). The patient was tested with standard commonly employed methods of non-invasive vascular testing equipment including carotid duplex scanning prior to and after 30 intravenous infusions. The patient initially had a 98% occlusion in the right internal carotid just beyond the bifurcation which was reduced to 33% after treatment. The shear motion present initially was replaced by normal arterial expansion after therapy.

Introduction

Diseases of the heart and great vessels have gone from relative obscurity in the 1920's to the number 1 health problem of the 1980's. Deaths from diseases of the carotid arteries ranks very high in our society and any therapy that affords effective, non-toxic and non-surgical therapeutic efficacy should be considered. Since C. Miller first described the clinical syndrome of carotid occlusive disease in 1951,¹ there have been increasing efforts to develop non-invasive tests for the diagnosis of common and internal carotid atherosclerotic lesions. The plethora of diagnostic procedures testifies to the difficulty in arriving at a fully satisfactory technique².

Dr. Rudolph is in private practice and is a partner at the McDonagh Medical Center, Incorporated in Gladstone, Missouri where Dr. McDonagh is the founder and partner. Address all correspondence to Charles J. Rudolph, Jr., DO, PhD, 2800-A Kendalwood Parkway, Kansas City, Missouri 64119.

The earlier techniques for assessing carotid occlusive disease involved assessing ophthalmic artery systolic pressures and comparative brachial systolic artery pressures using the technique of oculoplethysmography³. This technique gave semi-quantitative indications of the carotid physiologic blood flow but was incapable of assessing carotid artery stenosis at the level of the bifurcation or proximal internal carotid artery⁴. These non-invasive non-imaging techniques were replaced with imaging techniques as the resolution of the Doppler ultrasonic instruments became adequate to discern plaque in the 0.5 mm range⁵.

It is noteworthy that while there are several hundred published documents on non-invasive instrumentation and technique, there is little or no literature written on the results of non-surgical therapy for stenosis utilizing any of the current, commonly employed non-invasive treatments. This is hard to understand considering the fact that some conventional surgical treatments for carotid stenosis have poor long-term results^{6,7}.

Case Report

N.P., a 60-year-old lady, consulted us with a general complaint of fatigue. Physical exam was within normal limits including an absence of carotid bruits. A series of diagnostic tests were done which included plethysmographic studies.* After analysis of the pulse wave tracings, which showed reduced amplitude on the right side (Fig. 1), further evaluation of the carotid arteries was indicated. The patient was then examined by a Scannex SV ultrasonic high resolution advanced imaging unit.** This instrument has the capability of resolving a piece of arteriosclerotic plaque as small as 0.5 mm. After this initial study the patient received a course of thirty³⁰ infusions with intravenous disodium edetate and her diet was supplemented with multivitamins and trace minerals. On completion of treatment, carotid artery studies were repeated 68 days after the original examination. In both studies the carotid artery bifurcation was seen from the posterior view.

Results

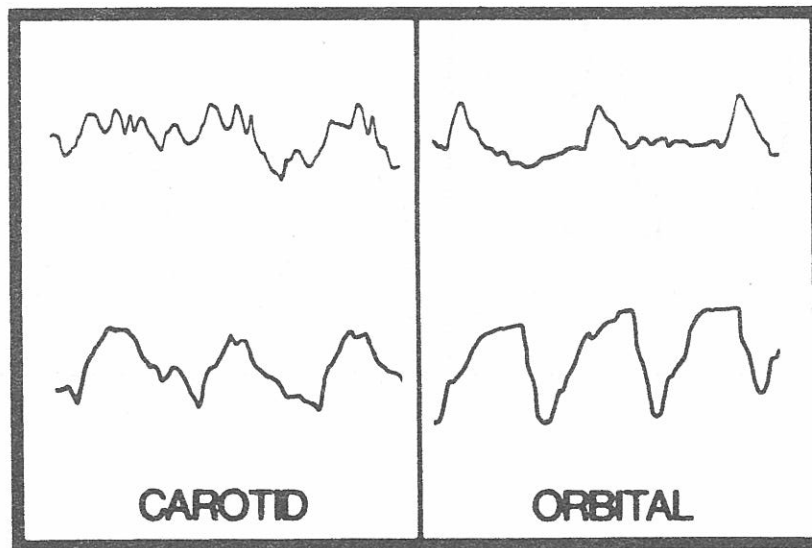
Because the benefits of chelation therapy are frequently delayed, our patients usually have the second scan of the carotid arteries delayed

*Cardioline vascular analyzer supplied by Cardiovascular Electronics, Benicia, CA.

**Supplied by Horizon Research Laboratories, Ft. Lauderdale, Florida

FIGURE 1

Plethysmographic tracings of patient N.P.'s right common carotid artery before (upper left) and after (lower left) therapy. The orbital arteries before (upper right) and after (lower right) are also included.



for 6 to 9 months. However, in this patient, the routine plethysmographic analyses of the common carotid and orbital arteries were so significantly improved (Fig. 1) that the duplex scan was also repeated. For comparison purposes, an essentially normal tracing on our plethysmographic vascular analyzer for the orbital and common carotid arteries is also depicted (Fig. 2).

Although the left internal carotid was shown to be normal, the right internal carotid was clearly shown to be 98% obstructed. A problem reporting this is that the artery is in a dynamic pulsating state and this feature is lost in scientific articles showing static images. This patient's arteries showed normal pulsation on the left. The right common and internal carotid arteries, however, pulsated by a phenomenon referred to as "shear motion". Shear motion is a phenomenon seen on the scan and is defined as a vertical, non-expansile motion that arteriosclerotic arteries exhibit due to the force of systole attempting to perfuse an artery that is greater than 95% occluded. This systolic energy, rather than expanding the artery along the arte-

FIGURE 2

Artists depiction of a normal plethysmographic tracing for a common carotid artery (left) and an orbital artery (right).

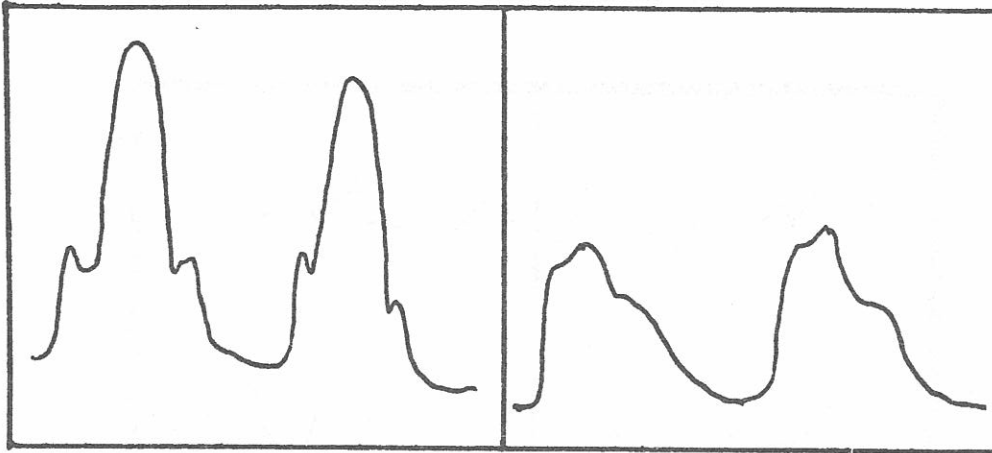


FIGURE 3

Scannex SV scans of patient N.P.'s common carotid artery bifurcation and proximal internal carotid artery before (left) and after (right) 30 infusions of EDTA.

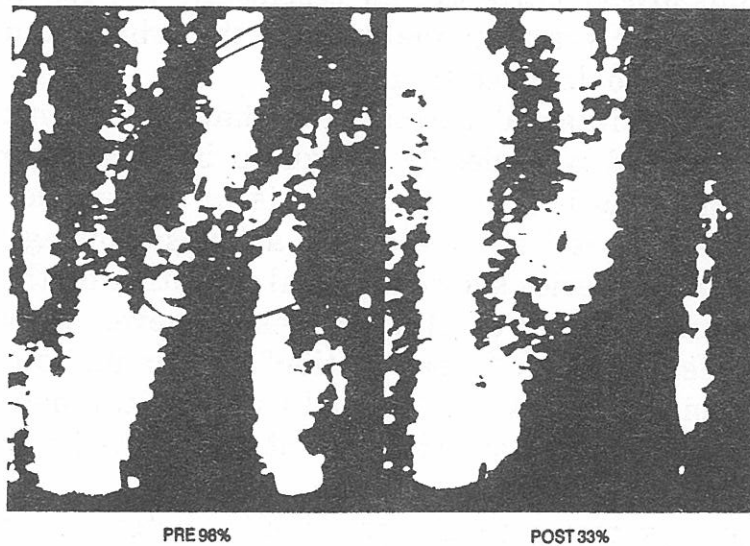
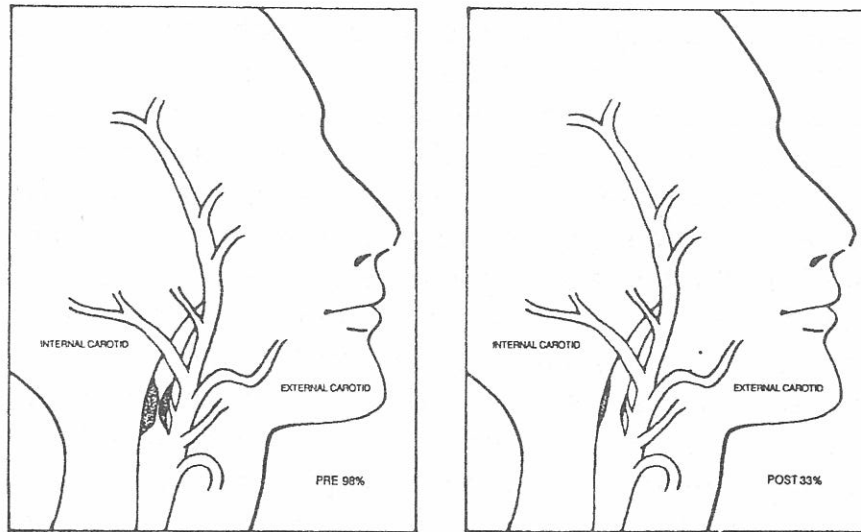


FIGURE 4

Artists depiction of the anatomical location of arteriosclerotic plaque in patient, N.P.'s right carotid artery before (left) and after (right) 30 EDTA infusions.



rial cross section, merely forces the plaque in a distal proximal motion along the vertical course of the artery.

In the second study, the previously 98% obstructed artery was only 33% obstructed (Fig. 3). An artist's depiction showing the location and size of the obstruction is also shown (Fig. 4). Further confirmation of this improvement in vascular stenosis is seen on the dynamic studies. Images of the right common carotid artery which, on initial examination, showed the shear motion previously described, revealed only normal cross sectional expansion after therapy. The shear motion had disappeared because of decreased occlusion in the internal carotid artery.

Discussion

Treatment with EDTA is used for lead and other heavy metal toxicity, digitalis intoxication and certain collagen disorders⁸. There is a growing number of physicians using this modality to treat the degenerative diseases resulting in metastatic calcification of the tissues,

namely arteriosclerosis and osteoarthritis. Theoretically, the chelate indirectly removes metastatic calcium deposits from the vessels, subsequently excreting bound calcium ions into the urine.

This report, to our knowledge, is the first attempt to examine the combined effects of intravenous EDTA therapy and multivitamin-trace mineral supplementation upon carotid stenosis. Improvement was demonstrated by using the popular imaging technique, Doppler ultrasonic imaging. McDonagh and associates published the first paper to show improvement in carotid arterial stenosis following EDTA chelation therapy using oculocerebrovasculometry. There was a reduction in stenosis from an average of 29% before therapy to an average of 10% after its completion⁹. Radionuclide studies, using Technetium-99, showed highly significant improvements in cerebral blood flow studies after 20 intravenous infusions of EDTA¹⁰. Finally, a large population study showing semi-objective improvement in post cerebrovascular accident patients has been recently reported¹¹.

At present, non-invasive study, with all its merits, is only marginally accepted as an appropriate diagnostic procedure. The "gold standard" is still angiography. B-mode Doppler imaging is, however, competitive because it also measures anatomical stenosis, as demonstrated here.

Conclusion

Intravenous EDTA chelation therapy has always suffered from the stigma that, while there are studies showing semi-objective improvement in patients receiving this therapy, there has not been any "hard core" proof that it results in improvement of arterial diameter. From the clinical improvement experienced by our patients, we have always been certain that there is an increase in the delivery of oxygen and micronutrients to the cell. Whether this derives from improved micro-circulation, or by complexing free iron and copper resulting in less free radical peroxidation¹², or both, is conjectural. This study shows without a doubt that this therapy improved the arterial blood flow for this patient, not only physiologically but also anatomically by reducing the amount of obstructive arteriosclerotic plaque in the large diameter arteries.

References

1. Fisher M: Occlusion of the internal carotid artery. *Arch Neurol Psychiat* 1951; 65:346-77.

2. Ackerman RH: Cerebrovascular survey report: non-invasive diagnosis of carotid disease. Washington, Joint Council Subcommittee on Cerebrovascular Disease. National Institute of Neurological and Communicative Disorders and Stroke and National Heart and Lung Institute 1980; 190-210.
3. Langham ME, To'Mey KF: A new procedure for the analysis of intraocular dynamics in human subjects. *Exp Eye Res* 1963; 2:314-24.
4. van Baalen C: Oculopneumoplethysmography and doppler spectrum frequency analysis in carotid artery disease, a comparative study. *Proc. San Diego Symp Non-Invas Diag Tech in Vasc Dis*, San Diego, CA, October, 1982.
5. Pfeifer JS, Barnes RW: Identification of intracranial carotid occlusive disease. *Bruit* 1982; VI:41-42.
6. EC/IC Bypass Study Group: Failure of extracranial to intracranial arterial bypass to reduce the risk of ischemic strokes. *New Engl J Med* 1987; 313[(19)]: 1191-1200.
7. Winslow CM, Solomon DH, Chassin MR, Kosecoff J, Merrick NJ, Brook RH: The appropriateness of carotid endarterectomy. *New Engl J Med* 1988; 318[(12)]: 721-727.
8. Walker FM: The effects of EDTA chelation therapy on plaque calcium and mineral metabolism in atherosclerotic rabbits, thesis for Doctor of Philosophy at North Texas State University, Denton, TX, May 1980.
9. McDonagh EW, Rudolph CJ, Cheraskin E: An oculocerebrovasculometric analysis of the effect of EDTA chelation upon vascular stenosis. *J Holistic Med* 1982; 4[(1)]: 21-23.
10. Casdorff R: EDTA chelation therapy II, efficacy in brain disorders. *J Holistic Med* 1981; 3[(2)]:101-117.
11. Carter J, Olszewer E: EDTA chelation therapy in chronic degenerative disease. *Med Hypoth* 1988; 27:41-49.
12. Frackleton J, Cranton E: Free radical pathology in age-associated diseases: Treatment with EDTA chelation, nutrition and anti-oxidants. *J Holistic Med* 1984; 6[(1)]:6-37.

